

## Case Report

# Successful recognition and management of life-threatening multivessel coronary artery vasospasm after conventional coronary artery bypass grafting.

Abdul Azeem Khan , Ahson Memon , Ghufanullah Khan ,  
Shakir Lakhani  & Vinod Kumar 

Department of Cardiothoracic Surgery, Tabba Heart Institute, Karachi-Pakistan.

Doi: 10.29052/IJEHSR.v11.i4.2023.219-223

**Corresponding Author Email:**

axeem.khan@tabbaheart.org

**Received** 02/05/2023

**Accepted** 26/09/2023

**First Published** 01/12/2023



## Abstract

**Background:** The occurrence of native coronary artery vasospasm after coronary artery bypass grafting (CABG) is a rare phenomenon with potentially catastrophic outcomes. The absence of a clear understanding of contributing factors and an undetermined occurrence rate underscores the importance of coronary angiography as the primary diagnostic tool for this condition.

**Case Presentation:** We present the case of a 70-year-old Asian male with a 14-year history of diabetes mellitus, seven years of Giant Cell Arteritis (GCA), and Ischemic Heart Disease (IHD). The patient experienced severe native coronary artery vasospasm following conventional CABG, prompting intervention through coronary angiography.

**Management & Results:** The patient underwent coronary angiography, revealing multivessel coronary artery vasospasm. Intracoronary administration of nitroglycerin and diltiazem was initiated promptly. The swift identification and treatment of vasospasm were instrumental in preventing severe myocardial injury.

**Conclusion:** Coronary artery vasospasm post-CABG poses a significant threat, emphasizing the need for early identification and intervention. The successful management presented in this case underscores the importance of timely recognition and the administration of vasodilators in mitigating potential myocardial damage. This report contributes to the growing understanding of this rare but critical complication, highlighting the necessity for vigilance in post-CABG patient care.

## Keywords

Coronary Artery Vasospasm, Coronary Artery Bypass, Postoperative Complications.



Check for  
updates

## Introduction

While Native Coronary Vasospasm is a rare occurrence in patients undergoing Coronary Artery Bypass Grafting (CABG), its potential to lead to catastrophic outcomes is well-documented<sup>1,2</sup>. The diagnostic challenge lies in the fact that coronary angiography remains the sole tool available for identifying this condition. The contributing factors to coronary vasospasm remain elusive, and the true occurrence rate is yet to be fully determined<sup>2,3</sup>. In this context, we present a case of severe and diffuse Native Coronary Vasospasm following CABG, emphasizing the importance of comprehensive management guided by a thorough literature review.

## Case Presentation

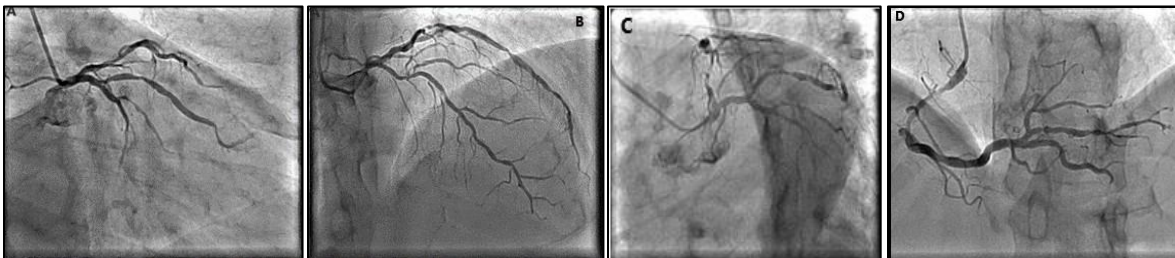
A 70-year-old Asian male, known for diabetes mellitus over the past 14 years and diagnosed with Giant Cell Arteritis (GCA) and Ischemic Heart Disease (IHD) for seven years, has been under conservative management with beta-blocking agents, Calcium Channel Blocker (CCB), Acetylsalicylic acid (ASA), oral hypoglycemics, and steroids (prednisolone). His previous Left Heart

Catheterization in 2014 revealed a two-vessel coronary artery disease, and the Myocardial Perfusion scan was negative. Regular cardiology follow-ups were maintained, with the patient initially in a stable condition.

However, after two months, the patient reported angina symptoms classified as CCS II-III on exertion. An echocardiogram revealed no valvular abnormalities and normal wall motion was observed. There were no indications of elevated cardiac enzymes, and the measured ejection fraction stood at 55%. The case presentation underscores the need for a detailed clinical evaluation to understand the evolving cardiovascular status of the patient.

## Management & Results

Following an elective Coronary Angiography, the patient's assessment revealed diffuse LM disease with moderate LAD disease and a fractional flow reserve (FFR) of 0.73 (A, B). Additionally, the RCA showed proximal stenosis of 50-60% (D), and critical lesions were identified in both obtuse marginal branches (C) (Figure 1 A, B, C, and D).



**Figure 1: Severe stenosis of the obtuse marginal branches as (A & C), and left anterior descending artery showing moderate stenosis proximally (FFR=0.73) (B). There is a severe proximal stenotic lesion of the right coronary artery (D).**

Subsequently, the patient was scheduled for elective surgery after a thorough consultation with the Cardiothoracic surgery department. Under general endotracheal anesthesia, a median sternotomy was performed to harvest the left internal thoracic artery (ITA). The patient underwent triple-vessel Coronary Artery Bypass Grafting (CABG) with a left internal mammary artery (LIMA) to the left anterior descending (LAD)

and saphenous vein grafts (SVG) to both the posterior descending (PDA) and the first obtuse marginal arteries (OM1). The procedure, lasting 120 minutes, was completed without complications, and the patient was promptly transferred to the ICU.

While the patient remained stable initially, a sudden onset of bradycardia (51 beats/min) and

hypotension (60/43 mmHg), accompanied by ST elevation in inferior leads and ST depressions in precordial leads, occurred after two hours. Interventions included increased inotropes, phenylephrine infusion, and heparin infusion. Despite stabilization, a similar event recurred after an hour, prompting an emergent graft study to assess anastomosis patency.

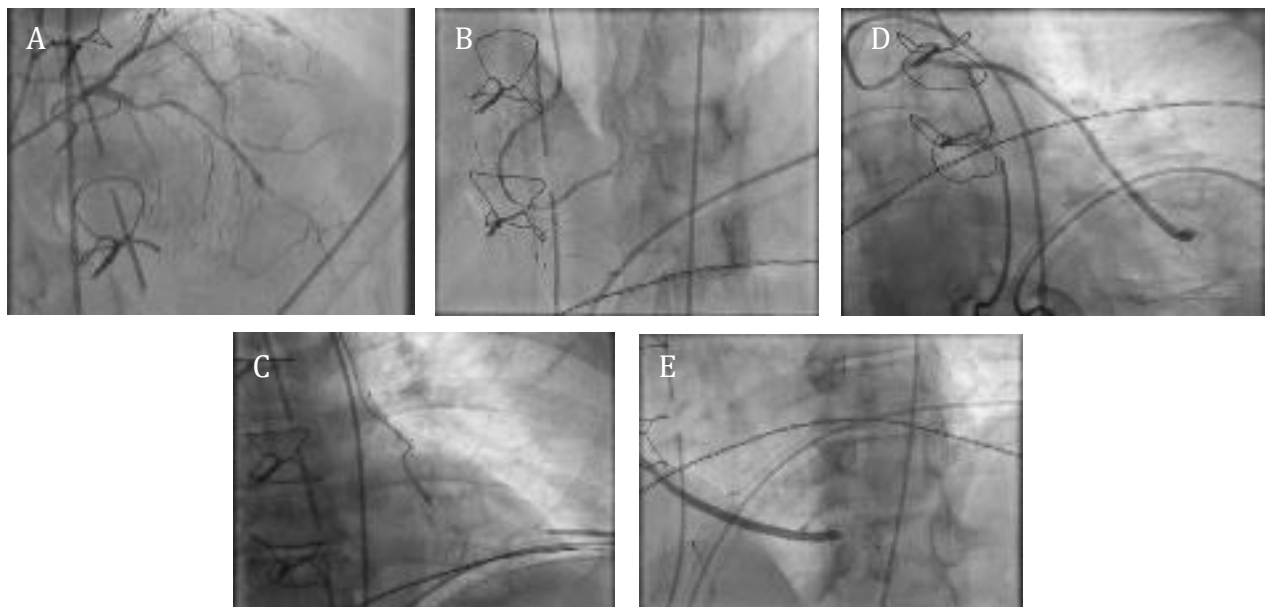
Emergent Coronary Angiography revealed severe vasospasm in both native bilateral coronary arteries, while LIMA and saphenous grafts remained patent (Figure 2).

Intracoronary vasodilators and calcium channel blockers were administered, showing limited improvement (Figure 3). Continuous infusions of nitroglycerin (3mg/hour) and diltiazem (2mg/hour) were initiated, but persistent ST-segment elevation persisted. High-dose catecholamine and intra-

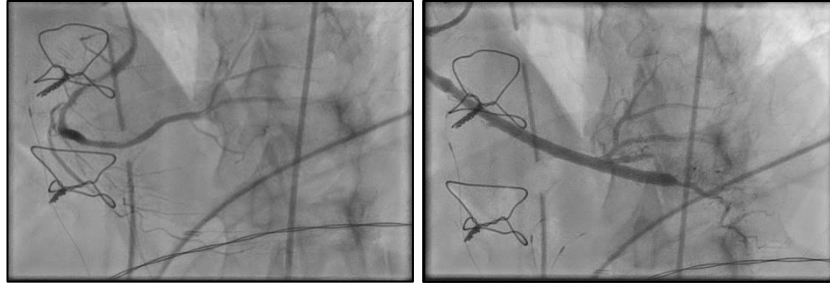
aortic balloon pump (IABP) were employed, yet the patient showed no improvement.

With the chest reopened in the ICU, active warming helped maintain blood pressure, allowing the weaning off of inotropes. The chest was closed the following day, and the patient was successfully weaned off inotropes. Extubation occurred on the subsequent evening, IABP removal followed, and the patient was transferred to the High Dependency Unit (HDU) on the 2nd post-operative day, later moving to the general ward. Prescribed medications included the oral vasodilator Nicorandil, Calcium Channel Blockers (CCBs), and Acetylsalicylic acid (ASA). Post-operative Echocardiogram revealed a normal ejection fraction (EF) and no wall motion abnormalities.

On the 7<sup>th</sup> post-operative day, the patient was discharged without further complications and is currently on regular follow-up.



**Figure 2: severely spastic native coronary as seen on Emergent post-operative Coronary Angiography (A&B). The venous graft and internal mammary artery to OM and PDA were all patents (C, D &E).**



**Figure 3: Coronary angiography done postoperatively with intracoronary GTN injection showed (A) relieved spastic right coronary artery, (B) patent PDA graft with distal good flow.**

## Discussion

In 1980, Pichard et al. reported the first CABG patient who developed Coronary artery vasospasm in the post-operative period<sup>1,2</sup>; however, cardiac surgery followed by Coronary Artery Vasospasm before CPB was reported by MacAlpin et al. in 1973<sup>1,2</sup>. Coronary vasospasm can occur right after CABG or during surgery. It is uncommon but has proven itself to be a severe complication<sup>1,4</sup>. Vasospasms can develop in both grafted and non-grafted vessels<sup>4,5</sup>.

Several potential factors postulated can lead to vasospasm. This includes the release of epinephrine and norepinephrine. In post CCB period, the release is high. Catecholamine injection preoperative can also be a cause. In the preoperative period, there is a high dosage of GTN, vascular injury during surgery, vascular endothelial injury site leading to platelet activation, focal area infiltrated with a high level of potassium, hyperventilation leading to respiratory alkalosis, hypomagnesemia, stimulation with a chest tube, hypothermia, and so forth<sup>1,4,5</sup>; however, the incidence rate of coronary artery spasm after surgery is still undetermined.

The coronary artery spasm after cardiac surgery is most commonly manifested by ST-segment elevation. The patient also comes with circulatory collapse without specific cause and most widely involves RCA. Still, in our case, all three vessels were in severe spasms<sup>1-3,5,6</sup>. Therefore, vasospasm should be resolved as a therapy target in patients with circulatory collapse due to coronary artery

spasm. CAG reveals the coronary vasospasm with an intracoronary infusion of adrenaline, which is considered the gold standard<sup>1,2,3,5</sup>. Urgent CAG and intraluminal injection of vasodilator are considered essential in this scenario<sup>1</sup>. Although vasodilating agents have been shown not to affect vasospasm in some cases, they can also induce life-threatening arrhythmia and circulatory collapse<sup>1,4,6</sup>. Rho-kinase inhibitors or nifedipine are considered important in treating this condition<sup>7-9</sup>. Another option that is deemed to be vital in treatment is intraluminal stent implantation<sup>7</sup>. This case was different as the spasm was involving the entire coronary artery. Stent placement was not considered as there were no indications to support it<sup>1</sup>. Applying IABP may play an essential role in supporting the ischemic myocardium, and chest reopening might also help. We deem that for treating disastrous vasospasm, a safe and efficient method is waiting and seeing policy along with supportive agents, considering that it is a reversible condition<sup>4,6</sup>. In our case, we managed the vasospasm by timely measures and saved the massive myocardial injury that was a significant concern in previous reports, and the patient survived.

## Conclusion

Identifying and predicting coronary artery vasospasm postoperatively is challenging due to various contributing factors, necessitating timely recognition and diagnostic interventions like coronary angiography for successful management. This case underscores the significance of early identification using angiography in the face of potentially lethal complications such as refractory

vasospasm. The use of adjuncts, including Intra-Aortic Balloon Pumps, chest reopening, and vasodilators, emerges as crucial in effectively managing complications post-coronary Artery Bypass Grafting (CABG). The comprehensive and adaptable approach applied in this case emphasizes the need for a nuanced strategy to address the complexities associated with post-operative coronary artery vasospasm.

---

### Conflicts of Interest

---

The authors declare no conflicts of interest.

---

### Acknowledgment

---

The authors want to thank all the staff and doctors who assisted in the management of this patient.

---

### Funding

---

No external funding was received for this study.

---

### References

---

1. Baek JH, Han SS, Lee DH. Native coronary artery and grafted artery spasm just after coronary artery bypass grafting: a case report. *JKMS*. 2010;25(4):641-643. doi: 10.3346/jkms.2010.25.4.641
2. Kim YH, Kim H, Chung YS, Kang JH, Chung WS, Shinn SH. Low cardiac output syndrome is caused by a coronary artery spasm following CABG. *Korean J Thorac Cardiovasc Surg* 2007; 40: 633-636.
3. Lorusso R, Crudeli E, Lucà F, De Cicco G, Vizzardi E, D'Aloia A, Gelsomino S. Refractory spasm of coronary arteries and grafted right coronary artery after off-pump coronary artery bypass grafting. *J Thorac Cardiovasc Surg* 2007; 133: 1649-1650. doi: 10.1016/j.athoracsur.2011.09.078.
4. Carneiro Neto JD, Lima Neto JA, Simões RM, Stolf NA. Coronary artery spasm after coronary artery bypass graft surgery without extracorporeal circulation: diagnostic and management. *Braz. J. Cardiovasc. Surg.* 2010;25(3):410-414. doi: 10.1590/S0102-76382010000300020
5. Tarhan IA, Kehlibar T, Arslan Y, Yilmaz M, Dumantepe M, Berköz K, Pancaroglu C, Ozler A. Effects of normothermic organ bath and verapamil-nitroglycerin solution alone or in combination on the blood flow of radial artery. *Eur J CardiothoracSurg* 2007; 32: 617-622. doi: 10.1016/j.ejcts.2007.06.039
6. He GW, Fan KY, Chiu SW, Chow WH. Injection of vasodilators into arterial grafts through the cardiac catheter to relieve spasm. *Ann Thorac Surg* 2000; 69(2): 625-628. doi: 10.1016/s0003-4975(99)01341-7.
7. Inokuchi K, Ito A, Fukumoto Y, Matoba T, Shiose A, Nishida T, Masuda M, Morita S, Shimokawa H. Usefulness of fasudil, a Rho-kinase inhibitor, to treat intractable severe coronary spasm after coronary artery bypass surgery. *J Cardiovasc Pharmacol* 2004; 44(3): 275-277.