

## Case Study

# Uterine arteriovenous malformation: A rare yet perilous entity.

Gul-e-Rana Abdul Mannan<sup>1</sup> , Rabiya Niaz<sup>1</sup> ,  
Durr-e-Shahwar Hayat<sup>2</sup> , Vyomesh Buch<sup>3</sup>  &  
Sarwat Ansari<sup>1</sup> 

<sup>1</sup>Department of Gynecology and Obstetrics, Canadian Specialist Hospital Abu hail-Dubai- UAE.

<sup>2</sup>Department of Radiology, Memon medical institute hospital Karachi-Pakistan.

<sup>3</sup>Department of Radiology, Canadian Specialist Hospital Abu hail-Dubai-UAE.

Doi: 10.29052/IJEHSR.v9.i4.2021.534-540

**Corresponding Author Email:**

hayatshahwar@gmail.com

**Received** 05/06/2021

**Accepted** 15/11/2021

**First Published** 29/11/2021



© The Author(s). 2021 Open Access This article is distributed under the terms of the Creative Commons Attribution 4.0 International License (<http://creativecommons.org/licenses/by/4.0/>)



## Abstract

**Background:** Uterine Arteriovenous Malformation (AVM) is a rare diagnosis. Although rare, it can cause massive and life-threatening hemorrhage, eventually leading to considerable morbidity and mortality. Healthcare professionals need to have a high index of suspicion in order to avoid morbidity associated with Uterine Arteriovenous Malformation. We shed light on this relatively under researched gynecologic diagnosis.

**Case Presentation:** We describe the presentation, workup, including radiological studies, and subsequent management of Uterine Arteriovenous Malformation in two reproductive-age females who presented to our hospital with abnormal vaginal bleeding. Both patients had a history of primary hemorrhage after abortion, requiring blood transfusion. Both patients underwent Magnetic resonance imaging (MRI) and showed a tortuous serpentine tangle of mixed signals extending from the deep myometrium into the endometrium.

**Management & Results:** Diagnosis of Uterine AVM was established months later when they presented with continuous abnormal vaginal bleeding. The diagnosis was established based on clinical examination and imaging studies. Patients were managed with hormonal treatment and responded well; one of them eventually got a successful pregnancy.

**Conclusion:** Uterine arteriovenous malformation, causing significant vaginal bleeding, can be managed timely with accurate diagnosis and prompt management, with an array of modalities including conservative, medical or surgical methods. The modality of treatment depends upon the patient's clinical condition and fertility wishes.

## Keywords

Uterine Arteriovenous Malformation, Hysteroscopy, Endometrial Curettage, Pyometrium, Endometritis.



Check for  
updates

## Introduction

Arteriovenous malformation (AVM) is an abnormal communication between arteries and capillaries without an intervening capillary network<sup>1</sup>. Uterine AVM can present with irregular, prolonged, or heavy vaginal bleeding<sup>2</sup>. Though considered rare, the true incidence of Uterine AVM is not understood well, as many of them respond to conservative and medical management of abnormal uterine bleeding. Fewer than 100 cases have been reported in the literature. Recently there has been an increase in reporting of uterine AVM due to better imaging facilities. It should be considered as a diagnosis in all cases of irregular uterine bleeding in reproductive age. Since Uterine AVM has the potential to cause torrential uterine bleeding, it is imperative to diagnose and treat it early to avoid a catastrophic outcome.

Moreover, attempting any invasive approach to diagnose uterine bleeding, including hysteroscopy, and specifically, endometrial curettage, can cause massive hemorrhage in case of an AVM. Thus, correct diagnosis is crucial. Transvaginal Ultrasound with Color Power Doppler is an accurate and efficient non-invasive diagnostic modality, with magnetic resonance imaging (MRI<sup>1</sup>) and Uterine Angiography used for further details. Management of AVM is multifactorial,

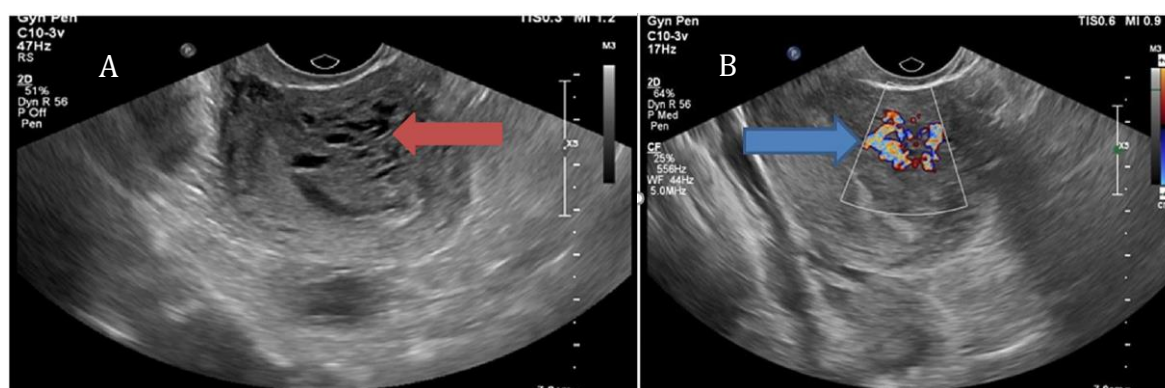
taking into consideration clinical presentation, amount of hemorrhage, and fertility wishes of the patient<sup>3</sup>.

This is a relatively under researched area in Gynecologic pathology. By presenting these cases, we want to emphasize all health care professionals to have a low index of suspicion for diagnosing Uterine Arteriovenous Malformation, in order to avoid morbidity and mortality associated with it.

## Case Presentation

### Case 1

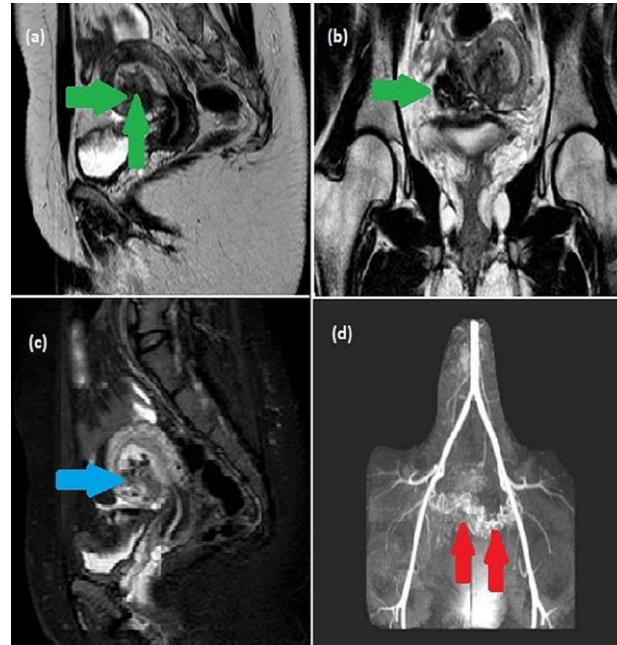
The patient is a 32-Year-old Para-0, Abortion-1, previously healthy female, that presented 2 months after a therapeutic abortion due to multiple congenital anomalies. She developed heavy vaginal bleeding immediately post-abortion, requiring blood transfusion. The cause of the bleeding remained undiagnosed. She continued having mild vaginal bleeding since then. Recently the bleeding became heavy with clots. On presentation, she was vitally stable. Beta human chorionic gonadotropin (Beta-HCG<sup>2</sup>) was negative. Transvaginal ultrasound showed irregular echogenic endometrium and endometrial cavity mildly expanded by hypoechoic fluid (Figure 1A).



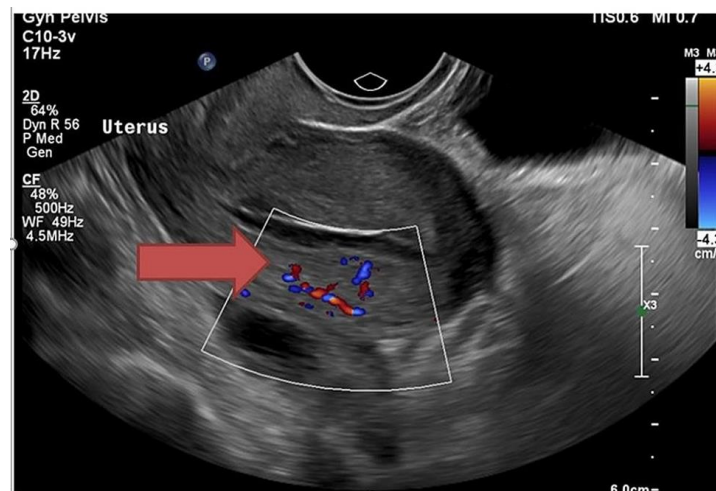
**Figure 1A: Transvaginal greyscale sonography showing myometrium having remarkable tortuous, tubular anechoic spaces in the anterior uterine wall (Red arrow). B: Transvaginal ultrasound with color doppler imaging showing high flow and low resistance vascularity in tortuous, tubular anechoic spaces within the anterior uterine myometrium (blue arrow).**

Myometrium showed remarkable tortuous vascularity in the anterior uterine wall, free fluid seen in the cul-de-sac, picture likely of pyometrium/endometritis and Arteriovenous malformation (AVM) was suspected (Figure 1B). The patient was started on oral antibiotics keeping the diagnosis of endometritis in consideration. Her bleeding subsided to some extent.

Next month she again presented with heavy vaginal bleeding. MRI pelvis showed a bunch of tortuous vessels within the myometrium at the right anterolateral aspect of the uterus extending to endometrium/sub-endometrium and bulging into the uterine cavity. They also seemed to extend into parametrium, more on the right side. The junctional zone at the site of the lesion was indistinct. Tortuous vessels were also noted around the vagina (Figure 2).



**Figure 2: MRI T2 weighted sagittal (a) and coronal images (b), STIR sagittal (c), and MRA (d) images showing a bunch of tortuous and rounded flow-related signal voids (approximately measuring 4.3 x 2.7 x 2.2 cm) within the myometrium at the right anterolateral aspect of the uterus extending to endometrium/sub-endometrium and bulging into the uterine cavity. They also seem to extend into parametrium more on the right side (green arrows). The junctional zone at the site of the lesion is indistinct (blue arrow). MRA (d) shows multiple dilated tortuous vessels arising from bilateral uterine arteries.**

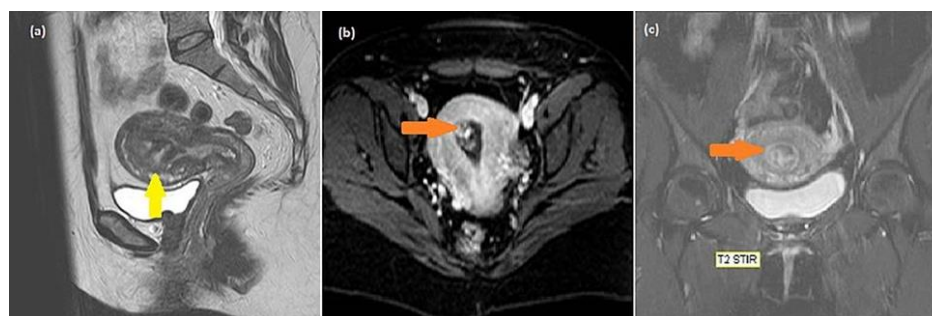


**Figure 3: Repeat transvaginal ultrasound after treatment which shows normal myometrium with a decrease in vascularity on color doppler imaging, suggesting no evidence of uterine AVM (shown by red arrow).**

## Case 2

Our second patient, a 33-year-old Para-1, presented to the hospital with an incomplete miscarriage with heavy vaginal bleeding. The patient underwent evacuation for retained products of conception under anesthesia. She bled heavily during the procedure, requiring 3 units of blood transfusion. Evacuation completed, and bleeding settled with uterotonics. After this acute event, she continued to have irregular, prolonged bleeding intermittently.

The patient didn't follow up, and 10 months after the miscarriage, she presented again with heavy vaginal bleeding. On examination, she was vitally stable with a soft and non-tender abdomen. The vaginal speculum revealed heavy bleeding with small clots. Beta-HCG was negative. Grayscale transvaginal ultrasound showed the uterus with homogenous myometrial echoes. The endometrium has heterogeneously hypoechoic lesions measuring 1.5 x 1.6 x 2.3cm with profound vascularity on color Doppler imaging. These findings were suggestive of uterine AVM. MRI of the patient confirmed the diagnosis of uterine AVM (Figure 4).



**Figure 4: MRI T2 weighted sagittal (a) and STIR axial (b), and coronal (c) images showing a tortuous serpentine tangle of mixed signals about 2.5 x 1.5 x 1.8 cm in size predominantly hyperintense and few small hypo-intense signals/flow voids on T2 and STIR images extending from the deep myometrium into the endometrium and bulging into the endometrial cavity at the fundus and right anterolateral aspect of the uterus (orange arrow). The junctional zone is slightly indistinct in this region (yellow arrow).**

## Differential Diagnosis

Diagnosis of Uterine AVM is made on typical imaging appearances in the absence of elevated serum b-hCG. In case beta-hCG is elevated, the differential diagnosis includes gestational trophoblastic disease and retained product of conception. These cases also give the same hypervascular appearance with turbulent flow. Such differentiation of diagnosis is very critical since curettage is not a treatment modality for Uterine AVM and, if done, may exacerbate bleeding.

## Management & Results

For case 1, a conservative approach was adopted since she was hemodynamically stable, in line with the patient's wish, and she was put on oral progesterone for bleeding control. Hormonal treatment was given to her for 3 months. She had clinical improvement in vaginal bleeding. Repeat transvaginal ultrasound

(TVS3) showed no sign of AVM (Figure 3). After 4 months of treatment, the patient conceived spontaneously and had a successful pregnancy outcome. Her follow-up after the delivery of her baby showed no complications. The patient in the second case was put on conservative management, which included oral progesterone (dydrogesterone) and antifibrinolytic (tranexamic acid) for 6 months. She responded to the medical treatment, and her bleeding subsided. Outcome and follow-up both patients had an uneventful recovery. Repeat transvaginal ultrasound of patient 1 showed no existence of Uterine AVM. The patient became pregnant 4 months after resolution of AVM and had a successful pregnancy and delivery. The pelvic ultrasound of patient 2 could not be done, but on follow-up, she had regular average flow menstrual cycles.

---

## Discussion

---

Uterine vascular malformations are a rare entity in the world of gynecology. It is an important differential to consider in all cases of unexplained uterine bleeding, both in reproductive age and postmenopausal women who have anechoic intrauterine structures<sup>4</sup>. Thus, a good understanding of diagnosis and management is imperative.

According to etiology, there are two types of Uterine AVMs, congenital and acquired, the latter being more common. Congenital Uterine AVMs arise from abnormal embryologic development of primitive capillary plexuses, leading to multiple abnormal connections and fistulas. They may present as an isolated case or in conjunction with AVMs at other site<sup>5</sup>. Acquired Uterine AVMs are secondary conditions that occur after uterine trauma due to abortion, uterine curettage, cesarean section, or pelvis surgery. They are also associated with infection, inflammation, and retained products of conception, gestational trophoblastic disease, gynecologic malignancies, and pelvic trauma, thus further complicating the management<sup>6</sup>. Both of our patients had a history of heavy bleeding during abortion requiring blood transfusion, thus falling into the acquired category.

Uterine AVMs invariably present with abnormal uterine bleeding. It is important to consider Uterine AVMs in irregular, unexplained, or heavy bleeding in any women of reproductive age<sup>7</sup>. It requires a high index of suspicion for timely diagnosis. Congenital AVM presents with menorrhagia, typically unresponsive to medical treatment. Whereas acquired AVM is suggestive from the history of associated risk factors.

Uterine AVM is diagnosed with typical clinical presentation, serum b-HCG being negative, and suggestive imaging picture. Large AVMs can present as pulsatile pelvic masses. A full ultrasound examination including color and spectral Doppler analysis is a valuable and cost-effective initial screening modality<sup>8</sup>. Greyscale ultrasound findings are non-specific, consisting of subtle myometrial

heterogeneity, multiple tubular or 'spongy' anechoic/hypoechoic areas within the myometrium, focal or asymmetrical endometrial and myometrial thickening, intramural uterine mass, endometrial mass, or cervical mass or sometimes as prominent parametrial vessels<sup>9</sup>. Doppler US shows hypervascularity, multiple tortuous feeding vessels, and turbulent flow. Spectral Doppler ultrasound shows arteriovenous shunts with low- resistance and high-velocity flow<sup>10</sup>. Though highly suggestive, these ultrasound findings are not pathognomonic. MRI is an excellent non-invasive approach to confirm the diagnosis and to see the extent of the disease. Characteristic appearances of AVM on spin-echo sequences of MRI are multiple serpiginous flow-related signal voids within the lesion<sup>10</sup>. The gold standard for diagnosis of uterine AVMs is digital subtraction pelvic angiography. It is used not only for diagnostic confirmation but particularly to delineate the feeder vessel in patients who are candidates for Uterine Artery Embolization<sup>8</sup>.

The principles of management revolve around hemodynamic status, age, fertility wishes of the patient, amount of bleeding as well as site and size of the lesion. After initial resuscitation, hysterectomy is the definitive treatment for massive bleeding or hemodynamic compromise when fertility is not desired<sup>8</sup>. Hysterectomy can also be done for symptomatic patients where UAE is technically not feasible, contraindicated, or failed. Other therapeutic options include uterine artery embolization, as well as, conservative management including hormonal treatment.

Uterine artery embolization is a well-recognized management option used widely in obstetric and gynecological hemorrhage. Few case reports show the effectiveness of this treatment modality in the management of uterine AVMs<sup>11</sup>. Peitsidis et al.<sup>1</sup> carried out an extensive systemic review, including studies dating from 1954 to 2011 (a total of 100 women), involving acquired AVMs developed following surgical uterine curettage. They found uterine artery embolization to be the most commonly used therapeutic option (59%), followed

by hysterectomy (29%). UAE has the major advantage of preserving uterine function due to extensive collateral vessels as compared to other surgical modalities. Due to the inconsistent effect of UAE on fertility, lack of high-quality, evidence-based data in this regard, and a theoretical risk of ovarian failure, may preclude this procedure as a fertility-preserving option.

The conservative approach, including hormonal medications, i.e., combined hormonal contraceptives<sup>12,13</sup>, progesterone, Gonadotropin-releasing hormone agonist (GnRH<sub>a</sub>)<sup>14,15</sup>, danazol and methylgonovine maleate<sup>16</sup> are feasible for hemodynamically stable patients with mild or irregular vaginal bleeding. Literature review revealed many case reports supporting the successful use of hormonal agents in regression of AVM<sup>12-16</sup>. Downregulation of estrogen secretion increased uterine arterial resistance and decreased uterine blood flow is postulated as the possible mechanism of action.

We used oral progesterone Dydrogesterone in our patients, and that led to complete resolution of their AVMs. Recently Taneja et al.<sup>17</sup> published a study where they successfully treated 27 out of 30 patients with postabortal symptomatic uterine AVM. Progesterone use results in stromal decidualization and subsequent thinning of endometrium, thus preventing exposure of AVM. Progestins act as powerful antiestrogens by helping to convert estradiol to estrone sulfate that rapidly gets cleared from the body. Furthermore, progestins antagonize estrogen action by inhibiting estrogen's induction of its receptors<sup>18</sup>. This hypoestrogenic state is thought to regress AVM.

---

## Conclusion

Uterine AVM is a rare but dangerous entity. With the increasing incidence of obstetric interventions or uterine instrumentation, the incidence of uterine AVMs can increase. Abnormal uterine bleeding is the most common presentation, which can be torrential in some cases. Pelvic ultrasound with Color and Spectral Power Doppler is a reliable non-invasive initial modality for diagnosis. Although

Hysterectomy and Uterine Artery Embolization have proven to be effective therapeutic options, conservative management with hormones leads to complete resolution in most cases, allowing for retained fertility and successful pregnancy outcomes. To avoid adverse outcomes from uterine AVM, a high index of suspicion with a prompt radiologic evaluation of the uterus is required in women presenting with abnormal uterine bleeding.

---

## Conflicts of Interest

The authors have declared that no competing interests exist.

---

## Acknowledgment

The authors would like to acknowledge the assistance and support of doctors and paramedical staff of Canadian Specialist Hospital in this case report.

---

## Funding

The author(s) received no specific funding for this work.

---

## References

1. Peitsidis P, Manolagos E, Tsekoura V, Kreienberg R, Schwentner L: Uterine arteriovenous malformations induced after diagnostic curettage: a systematic review. *Arch Gynecol Obstet.* 2011; 284:1137-1151.
2. Karadag B, Erol O, Ozdemir O, Uysal A, Alparlan AS, Gurses C, Koroglu M. Successful Treatment of Uterine Arteriovenous Malformation due to Uterine Trauma. *Case Rep Obstet Gynecol.* 2016:1890650.
3. Yoon DJ, Jones M, Taani JA, Buhimschi C, Dowell JD: A Systematic Review of Acquired Uterine Arteriovenous Malformations: Pathophysiology, Diagnosis, and Transcatheter Treatment. *AJP Rep.* 2016, 6:6-14.
4. Polat P, Suma S, Kantarcý M, Alper F, Levent A: Color Doppler US in the evaluation of uterine vascular abnormalities. *Radiographics.* 2002; 22:47-53.
5. Timmerman D, Wauters J, Van Calenbergh S, Van Schoubroeck D, Maleux G, Van Den Bosch T, Spitz B. Color Doppler imaging is a valuable tool for the diagnosis and management of uterine vascular malformations. *Ultrasound Obstet Gynecol.* 2003; 21:570-577.

6. Chang KH, Park JK, Park SH, Kim HB, Park ST. Uterine arteriovenous malformation caused by intrauterine instrumentation for laparoscopic surgery due to left tubal pregnancy. *Obstet Gynecol Sci.* 2014, 57:419-423.
7. Aziz N, Lenzi TA, Jeffrey RB Jr, Lyell DJ. Postpartum uterine arteriovenous fistula. *Obstet Gynecol.* 2004; 103:1076-1078.
8. Annaiah TK, Sreenivasan SK. Uterine arteriovenous malformations: clinical implications. *The Obstetrician & Gynaecologist.* 2015;17(4):243-250.
9. Huang MW, Muradali D, Thurston WA, Burns PN, Wilson SR. Uterine arteriovenous malformations: gray-scale and Doppler US features with MR imaging correlation. *Radiology.* 1998; 206(1):115-123.
10. Maldonado J, Perez C, Rodriguez W. AJR Teaching File: Profuse vaginal bleeding seven weeks following induced abortion. *AJR Am J Roentgenol.* 2008; 191:6.
11. Kim T, Shin JH, Kim J, Yoon HK, Ko GY, Gwon DI, Yang H, Sung KB. Management of bleeding uterine arteriovenous malformation with bilateral uterine artery embolization. *Yonsei Med J.* 2014; 55(2):367-373.
12. Nonaka T, Yahata T, Kashima K, Tanaka K. Resolution of uterine arteriovenous malformation and successful pregnancy after treatment with a gonadotropin-releasing hormone agonist. *Obstet Gynaecol.* 2011;117(2):452-455.
13. Oride A, Kanasaki H, Miyazaki K. Disappearance of a uterine arteriovenous malformation following long-term administration of oral norgestrel/ethinyl estradiol. *J Obstet Gynaecol Res.* 2014; 40:1807-1810.
14. Hammad R, Nausheen S, Malik M. A case series on uterine arteriovenous malformations: a life-threatening emergency in young women. *Cureus.* 2020;12(7):12.
15. Katano K, Takeda Y, Sugiura-Ogasawara M: Conservative therapy with a gonadotropin-releasing hormone agonist for a uterine arteriovenous malformation in a patient with congenital heart disease. *Clin Case Rep.* 2015;3(6):479-482.
16. Khatree MH, Titiz H. Medical treatment of a uterine arteriovenous malformation. *Aust N Z J Obstet Gynaecol.* 1999, 39(3):378-380.
17. Taneja A, Chopra I, Kaur H, Naik SS, Aggarwal R, Sachdeva E, Kaur P. Successful management of abnormal uterine bleeding from uterine arteriovenous malformations with progesterone in postabortal patients. *J. Obstet. Gynaecol. Res.* 45(6):1114-1117.
18. Dasgupta M. The estrogen and progesterone receptors in endometrial carcinoma - an update. *Endocrinol Metab Int J.* 2017; 5:211-214.