

## EVALUATION OF PATIENTS UNDERGOING TRANSARTERIAL CHEMOEMBOLIZATION (TACE) FOR HEPATOCELLULAR CARCINOMA WITH RESPECT TO TUMOR SIZE, SITE AND NUMBER OF LESIONS.

Amjad Sattar<sup>1</sup>, Shabbir Naeem<sup>2</sup>, Ahsan Ali<sup>2</sup> & Kiran Nazeer<sup>2</sup>

Dow University of Health Sciences.  
Sindh Institute of Urology and Transplant.(SIUT).

Corresponding author: amj7777@hotmail.com

### ABSTRACT

TACE is the combination of two procedures, an infusion of the mixture of chemotherapeutic agents (e.g. doxorubicin, cisplatin, or mitomycin C) and hepatic artery embolization in which particles such as polyvinyl alcohol or gelfoam, are injected simultaneously into selected branches of the hepatic artery supplying the tumor. Hepatocellular carcinoma is rarely seen before the age of 40 years and reaches a peak at around 70 years of age. Owing to its multicentricity, large tumor size and pre-existing cirrhosis most of these tumors were deemed unrespectable at the time of diagnosis. The purpose of this study was to evaluate the tumor size, site and number of lesions that is acquired on hepatic angiogram during TACE of the liver, and compare it with the information provided by pre-interventional contrast enhanced CT images as there is a possibility that CT may not show smaller lesions. This study was carried out in the Department of Angiography, Sindh Institute of Urology and Transplantation (SIUT) from May to October 2011. A total of 30 patients was included in the study. All individuals underwent pre-procedural imaging with contrast material, enhanced CT angiography or MR to ensure that the disease was liver-dominant and to visualize the blood vessels of the liver. This study included 30 patients age ranges 40-80 years, 22 of whom were males and 8 of them were females. HCC had been diagnosed in all patients. Each patient underwent selective Hepatic Chemoembolization in either the right, left or in both lobes. In comparison to CT, the hepatic angiogram showed 14(46.6%) patients having single lesion, 7(23.3%) were having double lesions and 9 (30%) were having multiple lesions. So the overall sensitivity of hepatic angiogram in the detecting number of lesions is 75 % - 80%. The size of  $\leq 2$ cm HCC was found in 12(35%) patients, HCC  $>3$ cm were found in 7(21%) patients and HCC  $>4$ cm was found in 15(44.4%) patients. The size of the HCC which we found in most of the patients during our study is  $>4$ cm.

### KEYWORDS

TACE, hepatic artery embolization, Hepatocellular carcinoma, Hepatic Chemoembolization

### INTRODUCTION

Liver cancer is the fifth most common cancer in the world among the male sex, taking the second place with respect to cancer related deaths. Conversely in the females it is the seventh most common cancer diagnosed and sixth leading cause of death (Wang Y, 2013). In Pakistan, the most common etiological factors have been reported as hepatitis B and aflatoxins (Kausar S 1998). The most common form of primary liver cancer is the hepatocellular carcinoma. Hepatocellular carcinoma is rarely seen before the age of 40 years and reaches a peak at around 70 years of age. Owing to its multicentricity, large tumor size and preexisting cirrhosis most of these tumors were deemed unrespectable at the time of diagnosis (Forner A, 2012). Due to these facts the transarterial chemoembolization (TACE) has gained immense popularity in the management of this disease (Llovet JM 2008).

The basis of TACE is the fact that the majority of the blood supply of hepatocellular carcinoma is derived from the hepatic artery. Therefore TACE is used either as an adjuvant therapy or as a palliative procedure for the unrespectable disease. It has been shown that TACE prior to surgical resection can not only prevent recurrence of carcinoma but also facilitate surgery by reducing tumor bulk (Xu KC 2009).

TACE is the combination of two procedures, an infusion of the mixture of chemotherapeutic agents (e.g. doxorubicin, cisplatin, or mitomycin C) and hepatic artery embolization in which particles such as polyvinyl alcohol or gelfoam, are injected simultaneously into selected branches of the hepatic artery supplying the tumor. Since the hepatic artery supplies nearly 100% of the blood supply of the malignant tumours of the liver, this renders the tumor tissue ischemic and hence accounting for the reduction in tumor size. Also this fact allows for higher intracellular concentrations of chemotherapeutic agents resulting in tumor necrosis while limiting damage to non

timorous liver (Transarterial chemoembolization Accessed on June 2013).

The purpose of this study was to evaluate the tumor size, site and number of lesions that is acquired on hepatic angiogram during TACE of the liver, and compare it with the information provided by pre-interventional contrast enhanced CT images as there is a possibility that CT may not show smaller lesions.

### MATERIALS AND METHOD

This study was carried out in the Department of Angiography, Sindh Institute of Urology and Transplantation (SIUT) from May to October 2011. A total of 30 patients was included in the study. Informed consent was taken from all the patients. These patients were referred from the Gastroenterology Department for TACE after being diagnosed as hepatocellular carcinoma.

TACE was performed in angiography unit. All procedures were performed on the Digital subtraction angiography machine (Toshiba KXO100 G) at frame rate 3 fr/s, 76kvp, 160mA and 39ms as per Department protocol. Medical, Surgical and contrast related history was taken and Informed consent was signed from all patients undergoing TACE.

All individuals underwent pre-procedural imaging with contrast material, enhanced CT angiography or MR to ensure that the disease was liver-dominant and to visualize the blood vessels of the liver. The main portal vein was ensured to be patent adequate portal perfusion was confirmed and collateral flow was ensured with hepatoportal flow (i.e. blood flowing toward the liver).

Pre-procedural patient preparation included hydration, fasting, steroids, bowel preparations and laboratory evaluation including complete blood count, prothrombin time, bleeding time, clotting time (INR), creatinine, urea and evaluation of liver and kidney function.

Subsequently, after all aseptic measures a local anesthetic was applied and a puncture was made in the common femoral artery with the help

of 19G Angio needle. Standard guide wire 0.035x150cm was introduced into the needle; 5fr angiographic vascular sheath was slid over the guide wire after the removal of the needle. A selective angiogram of the celiac trunk and superior mesenteric artery was performed to determine the origin and course of tumor-feeding vessels. Using micro catheter the feeding artery of HCC was cannulated super selectively and chemoembolic material and lipoidal injected. Pre medications include intravenous injection of 3cc nalbuphine (1ml diluted in 9cc of saline) and metoclopramide. Post procedure angiogram was done and repeated spot films were taken to confirm that the tumor had been optimally treated.

The post procedure care included management of the puncture site regarding bleeding and hematoma. Vitals were taken after every 30minutes for 4hours. Patients were asked not to move for 6hours at least. The post procedure medication for pain was administered to all patients.

## RESULTS

This study included 30 patients age ranges 40-80years, 22 of whom were males and 8 of them were females. HCC had been diagnosed in all patients. Each patient underwent selective Hepatic Chemoembolization in either the right, left or in both lobes. All procedures were performed successfully, without immediate (within 24 hours after chemoembolization) complications.

InCT Triphasic study out of 30 patients, we found 17 (56.6%) patients having single lesion, 6 (20%) were having double lesions, 6 (20%) were having multiple lesions and 1(3.3%)of the patient having no lesion. In comparison to CT, the hepatic angiogram showed 14(46.6%) patients having single lesion, 7(23.3%) were having double lesions and 9 (30%) were having multiple lesions. So the overall sensitivity of hepatic angiogram in detecting number of lesions is 75 % - 80%. (Figure 01)

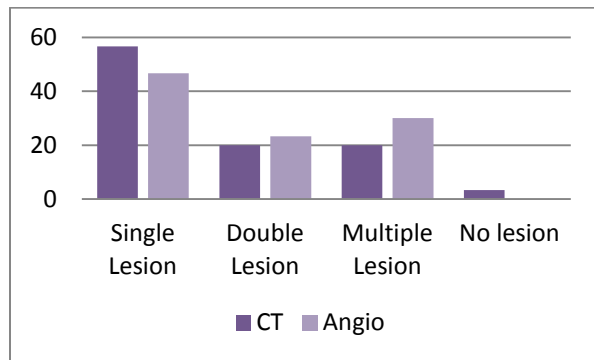


Figure 01: Number of lesions

Further on pre procedural imaging we found 5(16.6%)patients having a lesion in Left Lobe of Liver, 21(70%) patients having lesion in Right Lobe and 4(13.3%) patients were having lesion occupying both Lobes. Its mean that Right lobe of the Liver is more sensitive in having HCC lesion. (Table 01)

Site of Lesion	No of Patients
Lesion in Left Lobe	5 (16.6%)
Lesion in Right Lobe	21 (70%)
Lesion in Both Lobes	4 (13.3%)

Table 01: Site of Lesions

The size of  $\leq 2$ cm HCC were found in 12(35%) patients, HCC  $> 3$ cm were found in 7(21%)patients and HCC  $> 4$ cm was found in 15(44.4%)patients. The size of the HCC which we found in most of the patients during our study is  $> 4$ cm. (Figure 02)

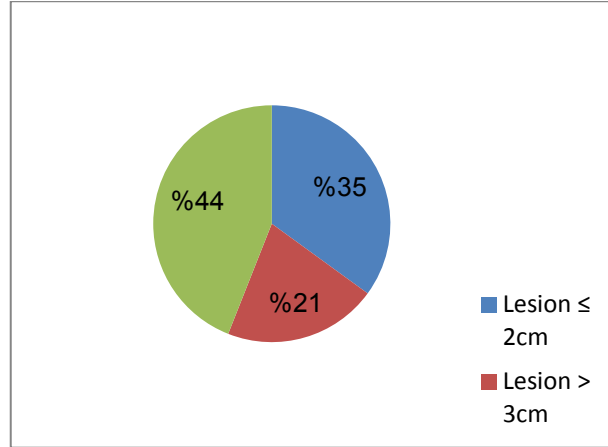


Figure 02: Size of Lesion

## DISCUSSION

Hepatic vascular interventions such as TACE are most likely to succeed when the target lesions are accurately identified by real-time angiography. However, owing to insufficient tumor vascularity or irregular enhancement of the background cirrhotic parenchyma, only 77% of hepatic tumors identified with previous MDCT are visualized with digital subtraction angiography(Iwazawa J 2010).

In the preoperative evaluation of hepatic tumors, the imaging studies used must be highly sensitive and specific for the detection of malignant neoplasms to enable the selection of appropriate surgical candidates and avoid unnecessary surgery. For this several imaging techniques are used to detect HCC. Several authors have evaluated the accuracy of CT imaging in detecting HCC nodules. They used histologic assessment of liver biopsy specimens, liver parenchyma taken by partial liver resection, or explanted liver at the time of liver transplantation as references and have reported a wide variety of sensitivities (40% to  $> 90\%$ ). Still, the question of whether Hepatic angiogram provides information beyond that obtained with other noninvasive modalities, as preoperative evaluation in the era of MDCT, remains to be addressed.

In recent years, a few studies have evaluated the role of multiphase scanning by MDCT in detecting small hypervascular HCC. They have drawn a conclusion that the utility of faster speed and thinner slice (6 mm) MDCT can improve the detectability of hypervascular small HCC, and additional early arterial phase imaging does not improve the detection of HCC compared with Tiphasic CT images (Zheng XH, 2005). With this in mind, we reviewed HCC cases using DSA and triphasic MDCT Technique in our institution.

It has been recognized that the majority of HCCs are hypervascular. During the hepatic arterial phase (HAP), hypervascular lesions are greatly enhanced, and become iso- or hypodense in the portal venous phase (PVP), which is a sensitive and specific feature for diagnosing HCC. A tiphasic hepatic acquisition helical CT scanning technique has become a standard method for clinical diagnosis of HCC (Baron RL 1996; Oliver JH 3rd 1996; Paulson EK 1998; Mitsuzaki K 1996). Meanwhile, hepatic angiography is widely used as an imaging technique for HCC. It has been known that the imaging techniques for detection and staging of HCC take advantage of two basic events: 1) the disappearance of portal vessels, which are substituted with arterial vessels; and 2) a progressive disappearance of the reticuloendothelial system (RES). MDCT has a remarkably greater sensitivity in detecting small neoplastic nodules ( $< 20$  mm). The advantage of MDCT scan is mainly due to the possibility of imaging the liver in the arterial phase (Zheng XH 2005).

In this study, all 30 patients had at least one overt HCC. We found that during MDCT, however, even with the most well timed IV bolus injection, the contrast medium is substantially diluted and scattered by the time it reaches the hepatic artery thus isolating a true arterial phase and a true portal venous phase may be difficult or even impossible. Since the triphasic helical CT does not have 100% sensitivity for detection of HCC, some lesion are liable to be missed especially the early HCC, as mentioned by Takayasu et al. (Yaqoob J 2004) which results in false-negative findings.

We examined our CT data on a lesion-by-lesion basis; we found that CT missed 10 of 34 HCC lesions measuring 1.5 cm or less. Another tumor nodule, which measured 2.8 cm, was not visible on CT. False negative results due to artifacts, partial-volume averaging, respiratory motion, and the rare iso-attenuating lesion at hepatic arterial and portal venous phases are additional factors that can lower the sensitivity of CT in the detection of HCCs (Teefey SA 2003).

CT findings are at times nonspecific and difficult to differentiate other hypervascular tumors from HCC. Therefore, MDCT has known limitations for the detection of liver lesions, especially small hypervascular lesions (Vallset al, 2004) evaluated the diagnostic accuracy of contrast-enhanced helical CT in 84 patients with liver cirrhosis before liver transplantation, using a contrast injection rate of 5 mL/s. Compared with the histopathologic results, the overall detection rate was 79%; however, the detection rate of lesions with a diameter less than 2 cm was 61%. This may offer an explanation for the higher detection rate of hypervascular masses on digital subtraction angiography compared with that on contrast-enhanced CT.

Conventional angiogram generates substantially more information than contrast enhanced CT triphasic. It delineates the exact location of the target tumor than perinterventional CT and MRI.

The Angiogram should, thus be able to provide delineation of tumor-feeding vessels and information about tumor location and extent, both of which could significantly influence the course of the intervention. Hepatic angiography has a dual advantage, during real time imaging we can generate a treatment plan which helps the radiologist to optimally block tumor feeding vessel.

In this study, we evaluated whether Conventional angiogram provides the same information regarding hepatic tumor spread in patients with hypervascular tumors as does state-of-the-art MDCT. Both methods were used to assess the extent of hepatic tumor involvement before TACE. Conventional angiogram may even increase the oncologic safety of the procedure because some false positive lesions seen on Conventional Angiogram might have been missed on MDCT. On the basis of the poor performance of CT for detecting small hypervascular lesions, some of the false-positive findings on C.A might actually have indicated true lesions that were not detected on MDCT (Peterson MS 2000; Iwazawa J 2009).

We examined our CT data on a lesion-by-lesion basis; we found that CT missed 10 of 34 HCC lesions measuring 1.5 cm or less. Another tumor nodule, which measured 2.8 cm, was not visible on CT.

Several limitations of our current study should be acknowledged. The most important is whether a lesion is the real target tumor or simply non tumor enhancement of DSA images is sometimes difficult to determine. Cirrhosis can cause inhomogeneous enhancement, resulting in enhanced pseudolesions, and organs such as the adrenal gland or gallbladder occasionally mimic true lesions. Furthermore we can not generate accurate treatment plan as MDCT can. A further limitation of this study is poor contrast resolution and lack of a true standard of reference for all lesions (Capasso P 1996).

Transarterial chemoembolizations require high spatial resolution and real-time imaging to guide and monitor the intervention. As in almost all percutaneous endovascular procedures, this is best accomplished using fluoroscopy. However, a major disadvantage of fluoroscopy

and angiography compared with cross-sectional imaging techniques such as CT or MRI is the possibility of missing soft tissue information regarding the target organs (Capasso P 1996).

Consequently the true sensitivity, specificity and accuracy of triphasic helical CT was also not possible. The results of our study show that the sensitivity of Hepatic angiograms is 75 – 80% in detecting number of lesions than those of CT triphasic. However this method being invasive is not commonly used in practice.

## REFERENCES

- Baron RL, Oliver JH 3rd, Dodd GD 3rd, Nalesnik M, Holbert BL, Carr B. (1996) Hepatocellular carcinoma: evaluation with biphasic, contrast-enhanced, helical CT. *Radiology*; 199: 505-511.
- Capasso P, Trotteur G, Flandroy P, Dondelinger RF. (1996) A combined CT and angiography suite with a pivoting table. *Radiology*; 199: 561-563
- Forner A, Llovet JM, Bruix J. (2012). Hepatocellular carcinoma. *Lancet*. 379:1245-55.
- Iwazawa J, Ohue S, Hashimoto N, Abe H, Hamuro M, Mitani T. (2010) *AJR Am J Roentgenol*. 195:882-7.
- Iwazawa J, Ohue S, Mitani T, Abe H, Hashimoto N, Hamuro M, et al. (2009 Apr) Identifying feeding arteries during TACE of hepatic tumors: comparison of C-arm CT and digital subtraction angiography. *AJR Am J Roentgenol*. ;192(4):1057-63.
- Kausar S, Shafiqat F, Shafi F, Khan AA. (1998). The association of hepatocellular carcinoma with hepatitis B and C viruses. *Pak J Gastroenterol* 12: 1-3.
- Llovet JM, Di Bisceglie AM, Bruix J, Kramer BS, Lencioni R, Zhu AX, Sherman M, Schwartz M, Lotze M, Talwalkar J, Gores GJ. (2008). Panel of Experts in HCC-Design Clinical Trials. Design and endpoints of clinical trials in hepatocellular carcinoma. *J Natl Cancer Inst*. 100:698-711.
- Meyer BC, Frericks BB, Voges M, Borchert M, Martus P, Justiz J, et al. (2008) Visualization of hypervascular liver lesions During TACE: comparison of angiographic C-arm CT and MDCT. *AJR Am J Roentgenol*. ;190:263-9.
- Mitsuzaki K, Yamashita Y, Ogata I, Nishiharu T, Urata J, Takahashi M. (1996) Multiple-phase helical CT of the liver for detecting small hepatomas in patients with liver cirrhosis: contrast-injection protocol and optimal timing. *Am J Roentgenol*; 167: 753-757
- Oliver JH 3rd, Baron RL, Federle MP, and Jones BC, Sheng R. (1997) Hypervascular liver metastases: do unenhanced and hepatic arterial phase CT images affect tumor detection? *Radiology*; 205: 709-715
- Oliver JH 3rd, Baron RL, Federle MP, Rockette HE Jr. (1996). Detecting hepatocellular carcinoma: value of unenhanced or arterial phase CT imaging or both used in conjunction with conventional portal venous phase contrast-enhanced CT imaging. *Am J Roentgenol*; 167: 71-77.
- Oliver JH 3rd, Baron RL. (1996) Helical biphasic contrast-enhanced CT of the liver: technique, indications, interpretation, and pitfalls. *Radiology*; 201: 1-14
- Paulson EK, McDermott VG, Keogan MT, DeLong DM, Frederick MG, Nelson RC. (1998) Carcinoid metastases to the liver: role of triple-phase helical CT. *Radiology*; 206: 143-150
- Peterson MS, Baron RL, Marsh JW Jr, Oliver JH 3rd, Confer SR, Hunt LE. (2000) Pretransplantation surveillance for possible hepatocellular carcinoma in patients with cirrhosis: epidemiology and CT based tumor detection rate in 430 cases with surgical pathologic correlation. *Radiology*; 217:743-749.
- Teefey SA, Hildeboldt CC, Dehdashti F, Siegel BA, Peters MG, Heiken JP, et al. (2003) Detection of primary hepatic malignancy in liver transplant candidates: prospective comparison of CT, MR imaging, US, and PET. *Radiology*. ;226:533-42.

- Transarterial Catheter Chemoembolization. Available at [http://en.wikipedia.org/wiki/Transarterial\\_chemoembolization](http://en.wikipedia.org/wiki/Transarterial_chemoembolization) Accessed on June 2013.
- Valls C, Cos M, Figueras J, Andía E, Ramos E, Sánchez A, et al.(2004)Pretransplantation diagnosis and staging of hepatocellular carcinoma in patients with cirrhosis: value of dual-phase helical CT. *AJR Am J Roentgenol.*;182:1011-7.
- Wang Y, Shen Y.(2013).Unresectable hepatocellular carcinoma treated with transarterial chemoembolization: clinical data from a single teaching hospital.*Int J ClinExp Med.*;6:367-71.
- Xu, K. C., Niu, L. Z., Zhou, Q., Hu, Y. Z., Guo, D. H., Liu, Z. P., ... &Zuo, J. S. (2009). Sequential use of transarterial chemoembolization and percutaneous cryosurgery for hepatocellular carcinoma. *World journal of gastroenterology: WJG*, 15(29), 3664.
- Yaqoob J, Bari V, Usman M U, Munir K, Mosharaf F, Akhtar W.(2004)The Evaluation of Hepatocellular Carcinoma with Biphasic Contrast enhanced Helical CT Scan *J Pak Med Assoc. ;54:123-7.*
- Zheng XH, Guan YS, Zhou XP, Huang J, Sun L, Li X, et al. (2005) Detection of hypervascular hepatocellular carcinoma: Comparison of multi-detector CT with digital subtractionangiography and Lipiodol CT. *World J Gastroenterol.*;11:200-3.